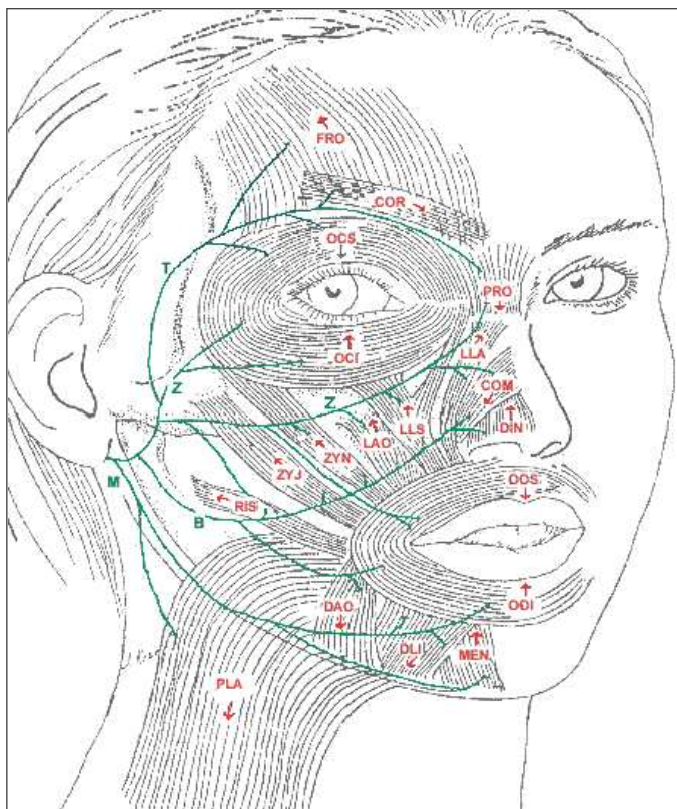


BELL'S PALSY INFORMATION SITE

The Facial Muscles



The arrows point in the direction of the muscle pull.

Muscle	Abbr.	Action
corrugator	COR	pulls eyebrows together downward and medially
depressor anguli oris	DAO	pulls the corner of the mouth downward as in frown
dilator naris	DIN	flares nostrils
depressor labii inferioris	DLI	draws lower lip downward and laterally
frontalis	FRO	raises eyebrows
levator anguli oris	LAO	elevates the angle of the mouth
levator labii superioris alaeque nasi	LLA	raises upper lip and dilates nostril
levator labii superioris	LLS	raises upper lip
mentalis	MEN	closes and protrudes the lips
orbicularis oris inferioris	OOI	closes and protrudes the lips
orbicularis oris superioris	OOS	closes and protrudes the lips
orbicularis oculi inferioris	OCI	closes the eye
orbicularis oculi superioris	OCS	closes the eye
platysma	PLA	draws corners of the mouth down, wrinkles neck
procerus	PRO	depresses medial corners of eyebrows (frown), wrinkles forehead
risorius	RIS	draws corner of mouth outward as in smiling
zygomaticus major	ZYJ	raises and draws corner of the mouth laterally (smile)
zygomaticus minor	ZYN	raises and everts upper lip

Major nerve branches: Temporal (T); Zygomaticus (Z); Buccal (B); Mandibular (M)

Not shown:

Buccinator - assists with chewing, blowing and whistling, and mouth closure.

Stapedius - dampens sound levels.